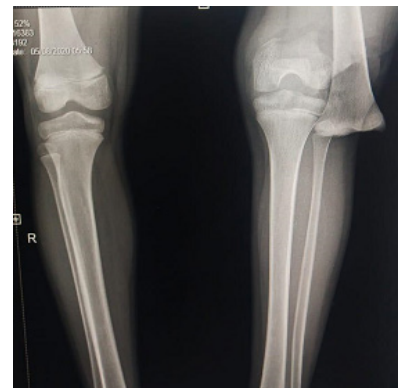
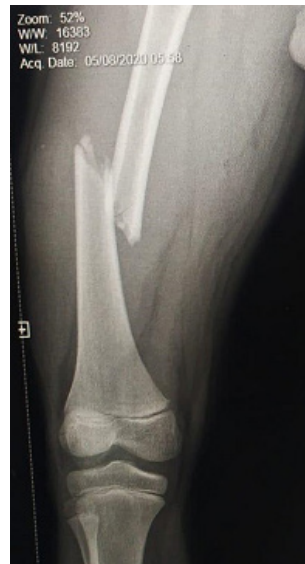
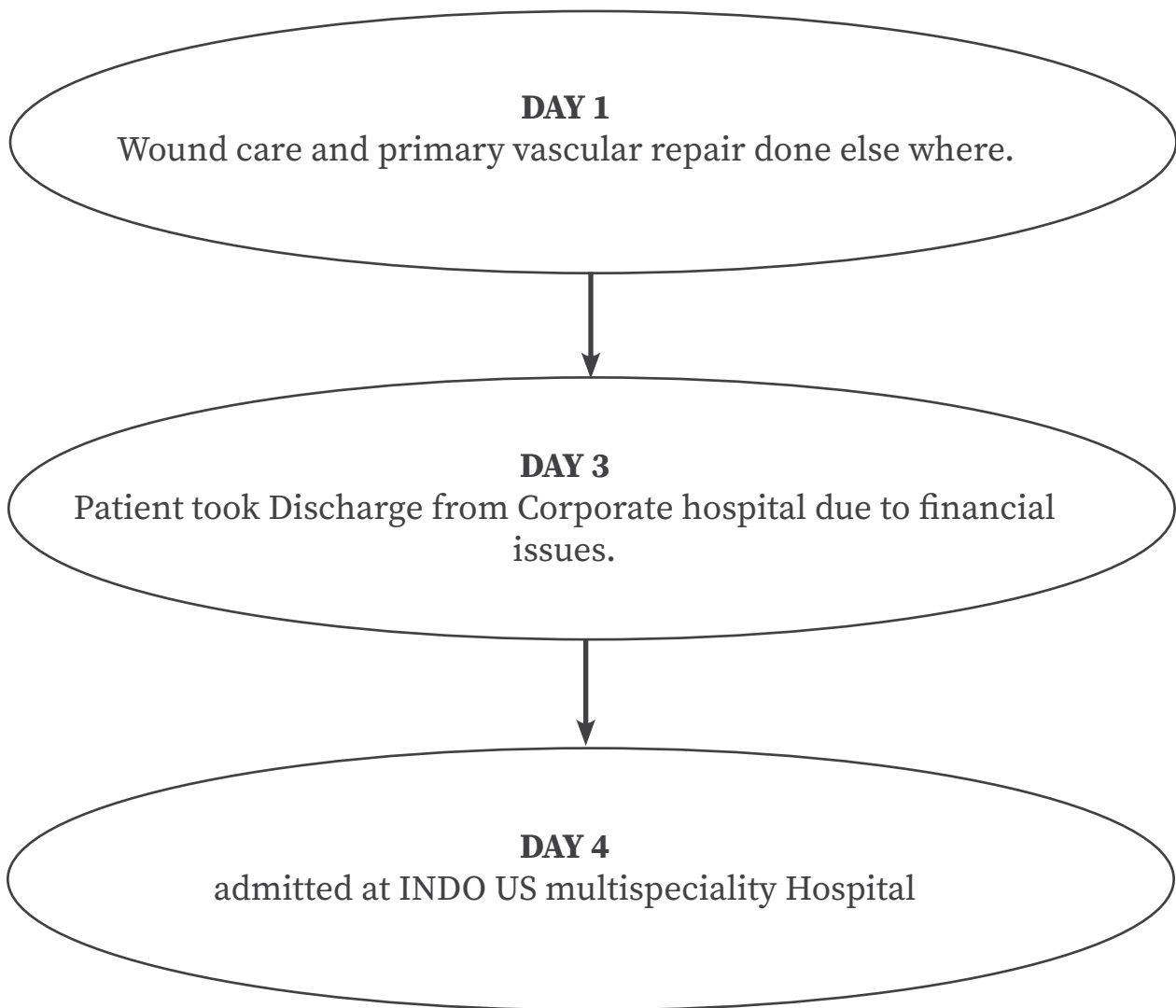
HIGH RISK POLY TRAUMA CASE

**13 years old boy:
Fell into the grilling machine.**

Sustained multiple injuries:

- Left distal femur physeal separation and popliteal vessel injury.
- Scrotal skin avulsion and exposed testis(rt).
- Perineum injury.
- Right femur fracture.
- Blunt Injury abdomen.
- Hypo-volemic Shock.





ISSUES AT THE TIME OF ADMISSION

- Hypo-volemic shock
- Sepsis
- Exposed testis
- Bleeding from vascular repair
- Femur fracture
- Calf skin necrosis with exposed soft tissue.

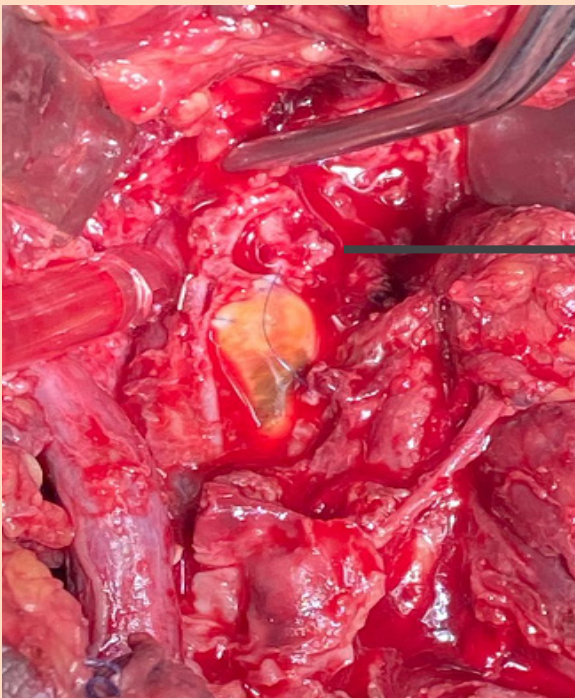
TREATMENT DONE

Step 1:

- Stabilization of general condition
- Blood transfusion
- Plan immediate surgery.

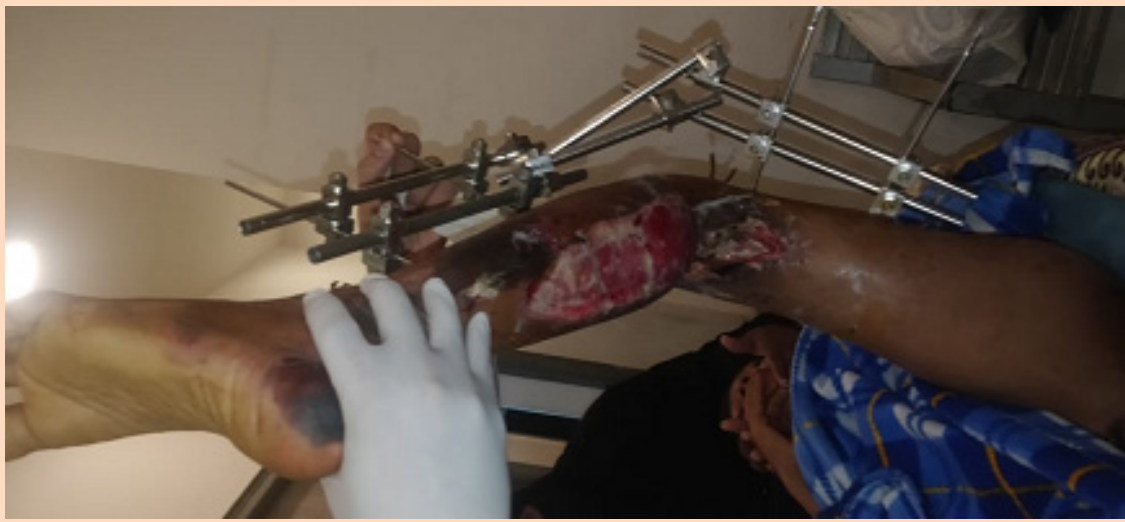Step 2:

- Vascular repair with Dacron graft under general anesthesia.
- External fixation for left knee
- Closed reduction and internal fixation Right femur
- Scrotal wound repair and perineum repair.

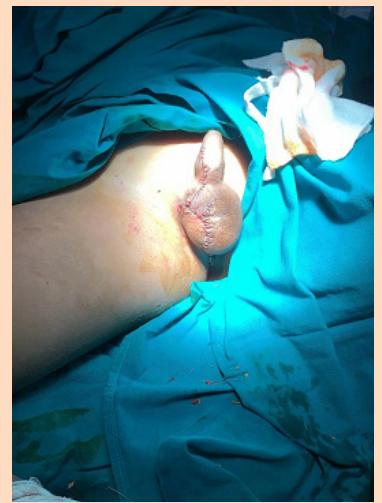

Vascular Rent

Repair with graft



Wound and external fixator in course of follow- up



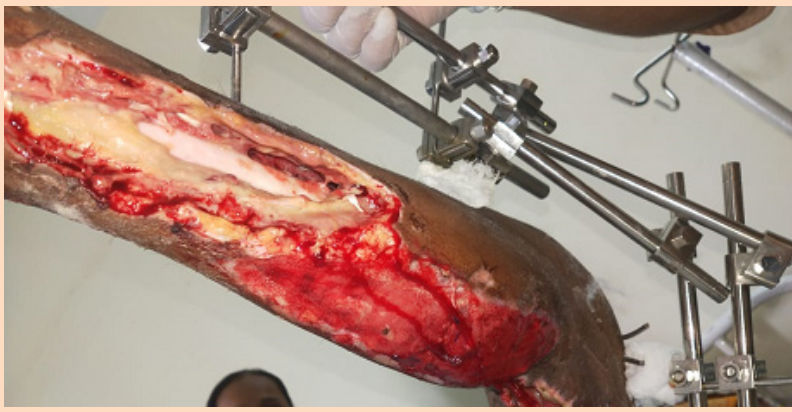
Scrotal wound after repair

Step 3:

- Debridement of the left leg necrotic tissue
- fibulectomy

Step 4:

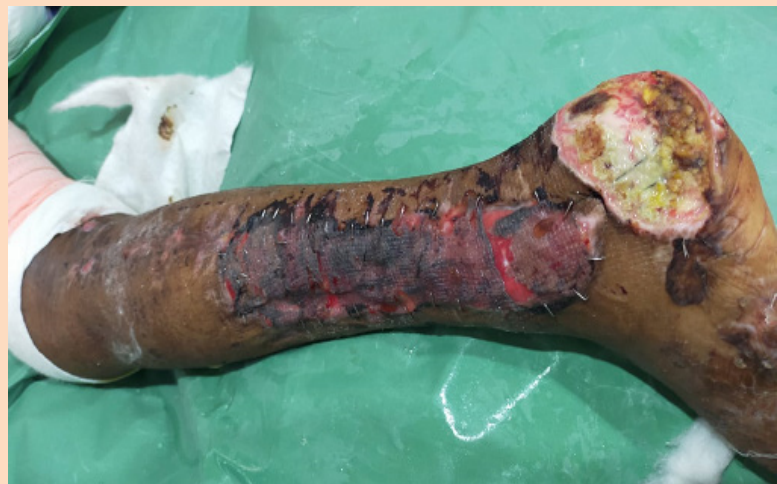- Skin Grafting of the residual wound of the left leg.



Unhealthy wound :

- necrotic tissue
- exposed devascularised fibula

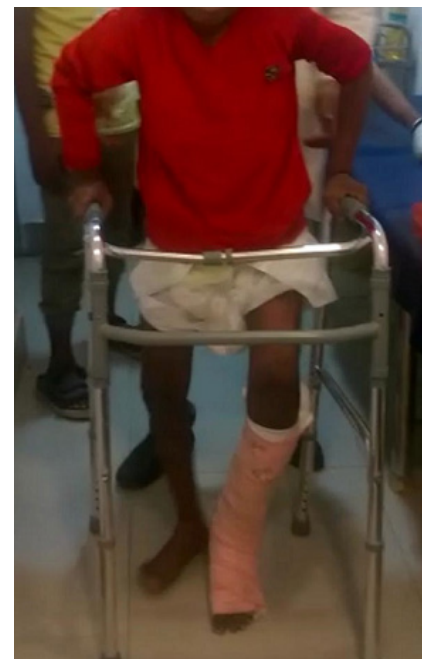Done debridement and fibulectomy.



Post skin grafting

3 months follow-up

- Vascular continuity regained: checked on Ultrasound
- Right femur fracture Union achieved
- Scrotal and perineum healed
- Skin graft taken up fully



Patient walking with support

